

Brain Localization

Central (UMN)= brain and spinal cord

Motor unit/peripheral (LMN)= nerve, neuron, NMJ, and muscle

KEY

- LMN = Lower Motor Neuron
- UMN = Upper Motor Neuron
- NMJ = Neuromuscular Junction
- CN = Cranial Nerve

Parts of the brain

→ forebrain (telencephalon and diencephalon)

→ cerebellum

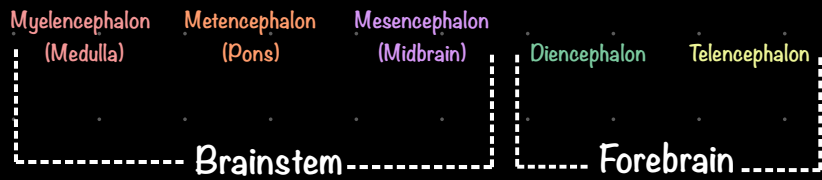
→ brainstem (myelencephalon, metencephalon, and mesencephalon)

— common names

→ myelencephalon = medulla

→ metencephalon = pons

→ mesencephalon = midbrain



Clinical Signs Associated with Different Parts of the Brain

Telencephalon (cerebral hemispheres)

- Seizures
- Behavior changes
- Vision deficits

Diencephalon (thalamus and hypothalamus)

- Telencephalon signs
- Endocrine disease

Mesencephalon (midbrain)

- CN 3-6
- Mentation (awareness)
- Gait

Cerebellum (dorsal metencephalon)

- Vestibular
- Cerebellar ataxia
- Dysmetria

Pontomedullary (pons and medulla together)

- CN 7-12
- Vestibular
- Mentation
- Gait

